

DOI: <https://dx.doi.org/10.18203/2319-2003.ijbcp20261969>

Case Report

Amiodarone causes QT prolongation in patients with atrial fibrillation complicating dyspepsia: a case report

Juniarto Mende*, Graciano Aristides Maturbongs, Yohana Krisostoma Anduk Mbulang

Departement of Pharmacy, Cenderawasih University, Jayapura, Indonesia

Received: 18 April 2026

Revised: 19 May 2026

Accepted: 26 May 2026

*Correspondence:

Dr. Juniarto Mende,

Email: juniarto.mende97@gmail.com

Copyright: © the author(s), publisher and licensee Medip Academy. This is an open-access article distributed under the terms of the Creative Commons Attribution Non-Commercial License, which permits unrestricted non-commercial use, distribution, and reproduction in any medium, provided the original work is properly cited.

ABSTRACT

A 62-year-old female patient presented to the hospital with complaints of dizziness, weakness, and fever for two days. On admission, her vital signs revealed an increased pulse rate and a temperature above normal. On the first day of hospitalization, her blood pressure rose to 145/94 mmHg before later fluctuating within the normal range. The patient's diagnosis included fatigue and febrile illness, dyspepsia, and AF RVR (Atrial fibrillation with rapid ventricular response). Subsequent laboratory tests showed elevated SGOT, SGPT, and CK-MB values above normal. Tests for HBSAg, anti-JAV, anti-HCV, and swab antigen were negative. During hospitalization, QT interval (QTc) prolongation was detected: the interval was 457 ms (Grade 1) on the second day and 481 ms (Grade 2) on the third day. Treatment began with Amiodarone 100 mg orally every 12 hours for the first two days. Additional medications included Bio Curliv (1 tablet every 8 hours orally), Zypraz (alprazolam) 0.25 mg once daily, tramadol 1 amp in 500 cc NaCl (infused over 8 hours as needed), Sistenol (N-acetylcysteine and paracetamol) 1 tablet every 8 hours orally, Norages (Metamizole) 1 ampoule on the first day, and Esomeprazole 1 tablet once daily. On the third day, Amiodarone was adjusted to 150 mg in 50 cc Dex 50% over 30 minutes, and then changed to 200 mg three times daily until discharge if the patient converted. Throughout treatment, pharmacists played an important role in monitoring for side effects, specifically QTc prolongation and elevated liver enzyme levels (SGOT and SGPT). Therefore, patients with AF require regular ECG monitoring to detect early QTc prolongation.

Keywords: Amiodarone, Atrial fibrillation, Elderly, Hepatotoxicity, QTc interval prolongation

INTRODUCTION

Atrial fibrillation (AF) is the most common cardiac arrhythmia, posing a significant healthcare burden.¹ This condition can lead to blood clots, stroke, heart failure, and other heart-related complications.² Kornej et al noted that the global incidence and prevalence of AF are increasing due to aging and chronic diseases, with higher rates seen in elderly patients.^{3,4}

AF and stroke remain major causes of morbidity and mortality. Both conditions share comorbidities and risk factors. Stroke with AF has a worse clinical outcome and higher mortality compared to stroke without AF.⁵ QTc is marker of ventricular repolarization on

electrocardiography.⁶ Prolongation of QTc interval is associated with a significantly higher risk of AF, with risk increasing with every 10 ms prolongation.^{6,7} QTc prolongation and high QT variability during sinus rhythm can be good predictors of ventricular and atrial arrhythmias.⁷

Antiarrhythmic medication is used as first-line treatment to restore and maintain sinus rhythm. A common side effect is QTc prolongation.⁸ Darbar et al reported that discontinuing medication for QT prolongation in patients with atrial fibrillation is protective, despite similar heart rates in AF and sinus rhythm.⁹ The purpose of this case report is to describe a problem related to the use of

amiodarone, which causes prolongation of the QTc in a patient with atrial fibrillation complicated by dyspepsia.

CASE REPORT

This 62-year-old female patient was admitted for atrial fibrillation with rapid ventricular response (AF RVR), fatigue, febrile illness, and dyspepsia. She had no history of allergies. After being hospitalized, she experienced persistent dizziness, weakness, and fever that developed over two days.

On examination, vital signs included a pulse rate of 118 beats per minute on the first day, decreasing to 102 beats per minute two days later. The temperature rose to 37.4°C on the second day and 38.5°C the next. Blood pressure increased to 145/94 mmHg initially and then fluctuated within the normal range.

Laboratory tests revealed negative HBsAg, anti-JAV, anti-HCV, and swab antigen. Laboratory examination, found on the first day of hospitalization there was a decrease in hemoglobin of 12.8 g/dl (normal: 13.2-17.3 g/dl), hematocrit decreased by 37.2% (normal: 40.0-54.0%), leukocytes increased by 10,560 cells/μL (normal: 5-10×10³ cells/μl), eosinophils decreased by 0.0% (normal: 2-4%), an increase in SGOT of 167.5 U/L (normal: 5-40 U/l), an increase in SGPT of 177.8 U/L (normal: 7-56 U/l), and an increase in CK-MB of 28.0 U/L (normal: 0-25 U/l). Subsequent tests revealed a decrease in hemoglobin of 11.9 g/dl, a decrease in hematocrit of 34.8%, an increase in leukocytes of 15,090 cells/μL, a decrease in eosinophils of 0.1%, and a decrease in segmented neutrophils of 21.5% (normal: 50-70%).

Urinalysis revealed red urine, a specific gravity of 1.025, a pH of 6.5, protein +2, leukocytes +4, negative Glimmer cells, and erythrocytes +5. Epithelial counts were +2, Ca oxalate negative, and bacteria +2.

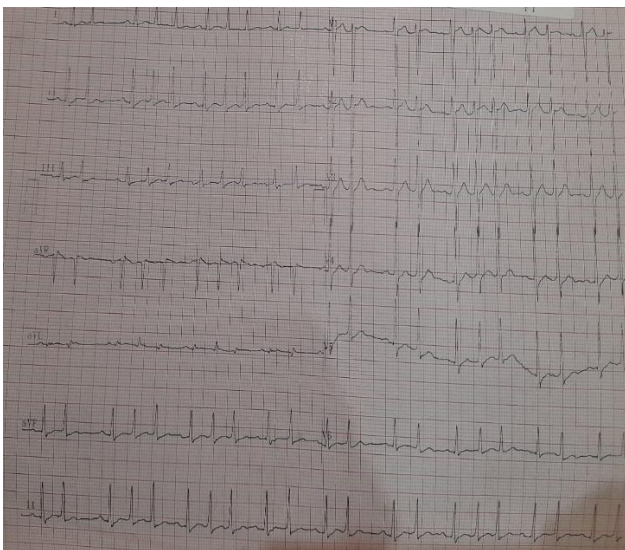


Figure 1: First day ECG results.

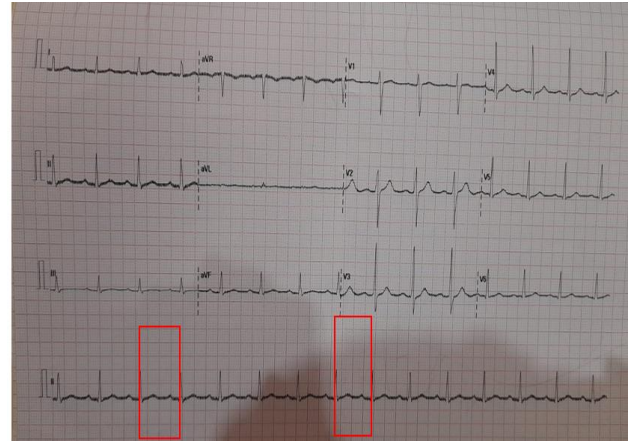


Figure 2: ECG results from day two.

QTc prolongation calculation (Day two)

Longest R-R → $18 \times 0.04 = 0.72 \rightarrow 60 : 0.72 = 83$ bpm

Shortest R-R → $15 \times 0.04 = 0.52 \rightarrow 60 : 0.6 = 100$ bpm

Average = 92 → need ventricular rate control.

Prolonged interval QT

QT = 360 ms

$RR = \sqrt{0.62} = 0.787$

QTc = $360 / 0.787 = 457$ ms (Grade 1).

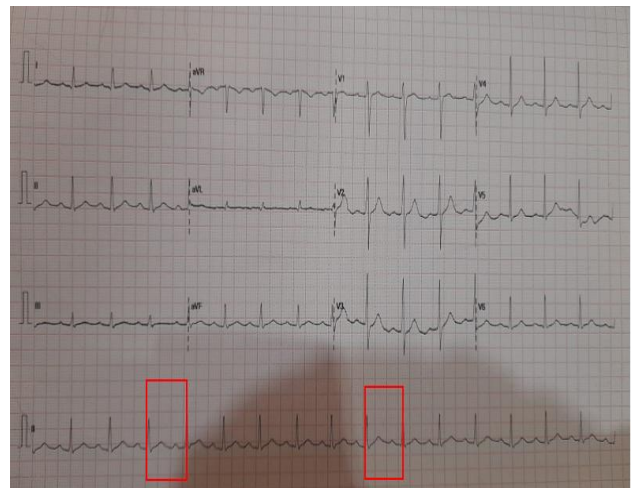


Figure 3: ECG results from day three.

QTc prolongation calculation (Day three)

Longest R-R → $15 \times 0.04 = 0.6 \rightarrow 60 : 0.6 = 100$ bpm

Shortest R-R → $13 \times 0.04 = 0.52 \rightarrow 60 : 0.52 = 115$ bpm

Average = 107 → need ventricular rate control.

Prolonged interval QT

QT=360 ms

RR= $\sqrt{0.56}$ =0.748

QTc=360/0.748

=481 ms (Grade 2)

DISCUSSION

AF is the most common long-term arrhythmia in adults. Rhythm control in patients with AF involves efforts to restore and maintain sinus rhythm and is performed with medication, catheter ablation, or electrical cardioversion.¹⁰ To further illustrate, recent ECG results and QTc interval calculations highlight key aspects in monitoring AF. For instance, the QTc value on the second day was 457 ms (Grade 1) and on the third day was 481 ms (Grade 2). Defining these terms, first-grade QTc prolongation is QTc >450 but ≤470 ms, while second-grade QTc prolongation is QTc >470 but ≤500 ms and/or an increase of ≥ 60 ms from baseline QTc. This prolongation represents a disturbance in the heart rhythm that may cause a rapid and irregular heartbeat. Evidence of this can be seen on ECG results by measuring the QTc.¹¹

Amiodarone is commonly used in rhythm control strategies, especially for supraventricular tachycardia.¹² It acts by blocking ion channels involved in action potentials, especially potassium channels. This results in QTc prolongation and slowed intraventricular conduction.¹³ Monitoring the use of amiodarone is important. A report from Cipto Mangunkusumo Hospital in Jakarta found significant QTc interval prolongation with amiodarone and with other QT-prolonging drugs. However, the study did not observe an increase in the extent of QTc prolongation when these drugs were used together; the effects were not additive.¹⁴ This underscores the importance of careful assessment when managing AF patients.

QT prolongation syndrome is caused by abnormal function of potassium and sodium ion channels expressed in both the ventricular and atrial myocardium.¹⁵ Furthermore, electrolyte imbalance is a highly prevalent clinical condition in emergency settings, highlighting the importance of recognizing drug interactions.¹⁶ QT prolongation in patients with coronary heart disease is a risk factor for polymorphic ventricular tachycardia and, consequently, sudden death.¹⁷

The ability to predict QT prolongation caused by drug interactions based on metabolic rate allows for improved safety of coadministration in patients with coronary heart disease.¹⁷ Similarly, in another study, amiodarone infusion was followed by the patient losing consciousness. Subsequently, the monitor displayed torsades de pointes (TdP) ventricular tachycardia, which rapidly converted to ventricular fibrillation.¹⁰

Amiodarone is a widely used antiarrhythmic drug that can cause liver injury and steatosis through various mechanisms. Repeated administration of amiodarone induces endoplasmic reticulum stress in both the liver and adipose tissue. In adipose tissue, amiodarone reduces lipogenesis and increases lipolysis.¹⁸ Cimic and Sirintrapun reported that amiodarone toxicity occurs in the liver (elevated liver enzymes) without phospholipidosis or steatosis.¹⁹ If there are signs of liver injury, amiodarone should be discontinued immediately, and supportive treatment should be initiated. The patient's liver enzymes return to normal levels.^{19,20}

Amiodarone-induced hepatotoxicity is characterized by steatosis, inflammation, fibrosis, and phospholipidosis. On liver biopsy, areas of hepatocyte damage and loss can be seen, leading to lobular collapse with inusoidal fibrosis and fibrotic bands that indicate early cirrhosis.²¹ In addition, Nagata et al report that CT scan results show high-density hepatotoxic areas in the liver.²² Importantly, a rare but potentially fatal side effect of amiodarone is acute liver failure, which is characterized by increased transaminases, increased total bilirubin, and mild leukocytosis occurring after amiodarone consumption.²⁰

Oral administration of N-acetylcysteine (NAC) 200 mg every 8 hours was indicated. NAC, a glutathione precursor with antioxidant, anti-inflammatory, and vasodilatory effects, helps address impaired liver perfusion and reduces hepatocyte apoptosis from oxidative stress and immune-mediated injury.^{23,24} Oxidative stress causes liver damage and contributes to steatorrhea, fibrosis, and liver dysfunction. NAC is used when elevated aminotransferases indicate liver injury and is recommended for improving liver function in non-acetaminophen-induced dysfunction.²³

According to Licata et al NAC improves hepatotoxicity and reduces mortality, with treatment lasting 8 to 24 hours.²⁵ This supplement aims to prevent liver damage in children, the elderly, and obese patients. Verma et al also indicate that NAC protects against mortality and hepatotoxicity caused by ascites fluid adsorbed (ad-AF).²⁶ Kaya et al show that NAC offers hepatoprotection and regulates oxidative stress parameters, MtrnL, Casp3, and HSP-70 immunoreactivity in the liver.²⁷

Bio Curliv is administered with a dosage of 1 caplet every 8 hours. Bio Curiv is a herbal supplement used as a supportive therapy to maintain liver function (hepatoprotective). Bio Curiv contains 150 mg of *Curcuma longa* rhizome extract, 35 mg of Sylmarin phytosome, 135 mg of Schizandrae fructus extract, 135 mg of Liguiritae radix, 150 mg of choline bitartrate, and 2 mg of vitamin B6. Curcumin has been linked to inhibition of lipid peroxidation, free radical formation, and DNA damage. Curcumin also has protective effects by downregulating nitric oxide synthase-2 (NOS-2) and reducing nitric oxide and lipid peroxidation products in the liver.²⁸

Curcuma longa rhizome contains curcumin, a compound with antioxidant properties. Curcumin captures superoxide ions and interrupts the chain reaction between ions. As a result, it helps prevent liver cell damage due to lipid peroxidation, working through SOD enzyme-mediated processes and reducing toxicity. Silymarin phytosome and Schizandrae extract act by increasing RNA synthesis and stimulating liver tissue regeneration. These actions improve liver cell membrane stability against xenobiotic damage, raise glutathione levels, and protect the liver from tetrachloride toxicity.²⁸

Regarding the patient's symptoms, the medical problem in this case was febrile with symptoms of weakness, fever, dizziness, and fluctuating pain levels. One ampoule of Metamizole was prescribed for this condition, followed by one tablet of tramadol every 8 hours. Metamizole is a non-steroidal anti-inflammatory drug with analgesic, antipyretic, and anti-inflammatory properties. The analgesic mechanism of metamizole is by inhibiting the activity of the cyclooxygenase enzyme to reduce prostaglandin synthesis.^{29,30} Metamizole is a safe treatment option compared to other widely used analgesics.³¹

At Airlangga University Hospital, intravenous metamizole effectively reduces fever in most pediatric inpatients.³² Hachimi-Idrissi et al found that metamizole reduces visual analogue scale (VAS) scores in patients with moderate pain.³³ For pain reduction or relief, the recommended dose is 500-1000 mg, to be taken 3-4 times daily. The maximum dose is 4 grams per day. Treatment should last 3-5 days.³⁴

Tramadol is an opioid pain reliever that works by binding to opioid receptors in the central nervous system to block or reduce pain signals to the brain, as well as by increasing serotonin and noradrenaline levels.³⁵ As an opioid prodrug, tramadol relies on the CYP enzyme to convert it to its active form, O-desmethyl tramadol, which influences the degree of opioid activity and thus its therapeutic effect.³⁶ Due to its centrally acting analgesic properties, tramadol is a treatment option for reducing chronic pain and is considered a second-line medication for moderate to severe pain.^{37,38} Notably, Inage et al report that tramadol use decreased VAS scores for low back pain from baseline.³⁹

Another medical problem in this case was dyspepsia. Dyspepsia is characterized by heartburn with fluctuating pain scales, and patients were given esomeprazole 1 amp/24 hours intravenously. PPI therapy is considered the first-line treatment for functional dyspepsia, with evidence showing that PPIs are more effective than placebo in managing functional dyspepsia, such as ulcers and reflux.^{40,41} Additionally, other reports suggest that PPIs are among the more effective drugs for treating acid reflux disease.⁴² In support of this, a study conducted by van Zanten found that of 502 patients, the esomeprazole group significantly reduced symptoms at four weeks, though not at eight weeks, compared to the placebo group.⁴³

CONCLUSION

Amiodarone use in patients with atrial fibrillation has side effects, including QTc prolongation and elevated liver enzyme levels (SGOT and SGPT). Regular ECG monitoring helps detect early QT prolongation. Dyspepsia requires comprehensive management of electrolyte abnormalities and drug interactions.

Funding: No funding sources

Conflict of interest: None declared

Ethical approval: Not required

REFERENCES

1. Saleh K, Haldar S. Atrial fibrillation: a contemporary update. *Clin Med.* 2023;23(5):437-41.
2. American Heart Association. Living With Atrial Fibrillation (AFib). American Heart Association. 2024.
3. Kornej J, Börschel CS, Benjamin EJ, Schnabel RB. Epidemiology of Atrial Fibrillation in the 21st Century: Novel Methods and New Insights. *Circulat Res.* 2020;127(1):4-20.
4. Karatela MF, Calkins H. The Global Impact of Atrial Fibrillation. *Arrhythm Electrophysiol Rev.* 2025;14:e28.
5. Elsheikh S, Hill A, Irving G, Lip GYH, Abdul-Rahim AH. Atrial fibrillation and stroke: State-of-the-art and future directions. *Curr Problems Cardiol.* 2024;49(1):102181.
6. Ding Q, Wang Z, Lu L, Song Z, Ge M, Zhou Q. QTc interval prolongation and risk of atrial fibrillation recurrence: a meta-analysis and observational cohort study. *Front Cardiovasc Med.* 2024;11:1483591.
7. Ninomiya Y, Enokizono K, Kawasoe S, Kubozono T, Kamada H, Iriki Y, et al. QT prolongation and excessive variability predicts new-onset atrial fibrillation in the health screening data of Japanese adults. Sethi Y, editor. *PLoS One.* 2025;20(10):e0333169.
8. Chelikam N, Kambhampati S, Katapadi A, Lakkireddy D. Dofetilide unmasks long QT in a patient presenting with atrial fibrillation-induced cardiomyopathy. *HeartRhythm Case Rep.* 2024;10(10):717-20.
9. Darbar D, Kimbrough J, Jawaid A, McCray R, Ritchie MD, Roden DM. Persistent Atrial Fibrillation Is Associated with Reduced Risk of Torsades de Pointes in Patients with Drug-Induced Long QT Syndrome. *J Am College Cardiol.* 2008;51(8):836-42.
10. Stojanovic M, Nikolic M, Nedeljkovic I, Gojkovic D. QT Prolongation Preceding Ventricular Fibrillation After Amiodarone Administration: A Case Report. *Cureus.* 2024;16(7):e63763.
11. Curigliano G. QTc prolongation assessment in anticancer drug development: Clinical and methodological issues. *eCancer.* 2009;3:130.
12. Hindricks G, Potpara T, Dagres N, Arbelo E, Bax JJ, Blomström-Lundqvist C, et al. 2020 ESC Guidelines for the diagnosis and management of atrial fibrillation developed in collaboration with the European Association for Cardio-Thoracic Surgery (EACTS). *Europ Heart J.* 2021;42(5):373-498.

13. Nordkin I, Levinas T, Rosenfeld I, Halabi M. Torsades de pointes after prolonged intravenous amiodarone therapy for atrial fibrillation. *Clin Case Rep.* 2021;9(1):391-4.
14. Nafrialdi, Kurniawan TG, Setiawati A, Makmun LH. QT Interval Prolongation Associated with Amiodarone Use in Cipto Mangunkusumo Hospital, Jakarta. *Acta Medica Indonesiana.* 2014;46(4):292-7.
15. Platonov PG, McNitt S, Polonsky B, Rosero SZ, Zareba W. Atrial Fibrillation in Long QT Syndrome by Genotype. *Circ: Arrhythmia Electrophysiol.* 2019;12(10):e007213.
16. Campinas A, Pereira Santos M, Sousa MJ, Gomes C, Torres S. Amiodarone-Induced Electrical Storm: A Nightmare in the Emergency Room. *Cureus.* 2023;15(11):e49494..
17. Ismagilov AD, Shikh EV, Sizova ZM, Shindryaeva NN. Prolongation of the QT interval in patients with coronary heart disease as consequence of drug-drug interactions on metabolic rate. *Electron J Gen Med.* 2018;15(4):em68.
18. Hubel E, Fishman S, Holopainen M, Käkälä R, Shaffer O, Hourri I, et al. Repetitive amiodarone administration causes liver damage via adipose tissue ER stress-dependent lipolysis, leading to hepatotoxic free fatty acid accumulation. *Am J Physiol Gastroint Liver Physiol.* 2021;321(3):G298-307.
19. Cimic A, Sirintrapun J. Amiodarone Hepatotoxicity with Absent Phospholipidosis and Steatosis: A Case Report and Review of Amiodarone Toxicity in Various Organs. *Case Rep Pathol.* 2013;2013:1-4.
20. Calderon-Martinez E, Landazuri-Navas S, Kaya G, Cinicola J. Chronic Oral Amiodarone as a Cause of Acute Liver Failure. *J Med Cases.* 2023;14(2):59-63.
21. Buggie J, Kappus M, Lagoo AS, Brady CW. Amiodarone-Induced Liver Injury and Cirrhosis. *ACG Case Rep J.* 2015;2(1):116-8.
22. Nagata T, Takata K, Shakado S, Hirai F. Amiodarone-induced hepatotoxicity. *BMJ Case Rep.* 2023;16(11):e256679.
23. Bauerlein DK, Akbar HN, von Rosenvinge EC, Loughry ND, John PR. Benefit of N-Acetylcysteine in Postoperative Hepatic Dysfunction: Case Report and Review of Literature. *Case Rep Hepatol.* 2019;2019:1-4.
24. Pulley JM. Acetylcysteine (N-acetylcysteine, NAC) for the management of non-acetaminophen-induced acute liver failure. *Vanderbilt Institute for Clinical and Translational Research.* 2020.
25. Licata A, Minissale MG, Stankevičiūtė S, Sanabria-Cabrera J, Lucena MI, Andrade RJ, et al. N-Acetylcysteine for Preventing Acetaminophen-Induced Liver Injury: A Comprehensive Review. *Front Pharmacol.* 2022;13:828565.
26. Verma A, Mallick P, Dwivedi P, Singh A. Exogenous supplementation of N-acetylcysteine can reduce hepatotoxicity induced by ascites fluid (cell-free) adsorbed over Protein-A-containing *Staphylococcus aureus* Cowan-I without compromising its antitumor effect[†]. *J Pharm Bioall Sci.* 2019;11(3):205.
27. Kaya S, Yalcın T, Tektemur A, Kuloğlu T. N-Acetylcysteine may exert hepatoprotective effect by regulating Meteorin-Like levels in Adriamycin-induced liver injury. *Cell Stress Chaperones.* 2023;28(6):849-59.
28. Farzaei M, Zobeiri M, Parvizi F, El-Senduny F, Marmouzi I, Coy-Barrera E, et al. Curcumin in Liver Diseases: A Systematic Review of the Cellular Mechanisms of Oxidative Stress and Clinical Perspective. *Nutrients.* 2018;10(7):855.
29. Miljković M, Rančić N, Simić R, Stamenković D, Dragojević-Simić V. Metamizole: Current status of the safety and efficacy. *Hosp Pharm Int Multi J.* 2018;5(3):694-704.
30. Stromer W, Fontanilla P, Cywińska-Durczak B. Safety of metamizole superior to comparable OTC analgesics. *Evidence Self-Medicat.* 2025;5:1-4.
31. Kötter T, da Costa BR, Fässler M, Blozik E, Linde K, Jüni P, et al. Metamizole-Associated Adverse Events: A Systematic Review and Meta-Analysis. *Manzoli L, editor. PLoS ONE.* 2015;10(4):e0122918.
32. Puspitasari AD, Azizah AN, Nilamsari WP, Nurhariansyah R, Palupi IN. Utilisation study of antipyretic drugs in paediatric patients. *Pharm Educ.* 2024;24(3):234-9.
33. Hachimi-Idrissi S, Coffey F, Dobias V, Hautz W, Leach R, Sforzi I. Guidelines for the management of acute pain in emergency situations. *The European Society for Emergency Medicine (EUSEM), Aartselaar Belgium.* 2020.
34. Wertli MM, Flury JS, Streit S, Limacher A, Schuler V, Ferrante AN, et al. Efficacy of metamizole versus ibuprofen and a short educational intervention versus standard care in acute and subacute low back pain: a study protocol of a randomised, multicentre, factorial trial (EMISI trial). *BMJ Open.* 2021;11(10):e048531.
35. Subedi M, Bajaj S, Kumar MS, Yc M. An overview of tramadol and its usage in pain management and future perspective. *Biomed Pharmacoth.* 2019;111:443-51.
36. O'Connor J, Christie R, Harris E, Penning J, McVicar J. Tramadol and Tapentadol: Clinical and Pharmacologic Review. *World Federation Societies Anaesthesiologists.* 2019;1-6.
37. Khan TB, Singh A, Rani D. Tramadol use for chronic pain management: A thorough analysis of safety, effectiveness, and clinical recommendations. *GJHSR.* 2024;3:11-4.
38. Blondell RD, Azadfard M, Wisniewski AM. Pharmacologic Therapy for Acute Pain. *Am Family Phys.* 2013;87(11):7.
39. Inage K, Sainoh T, Okuyama K, Yamashita M, Ohyama S, Fujimoto K, et al. The Analgesic and Side Effects of Tramadol Hydrochloride Immediate-Release and Extended-Release Tablets in Patients with Chronic Low Back Pain. *Cureus.* 2024;16(10):1-6.
40. Harer KN, Hasler WL. Functional Dyspepsia: A Review of the Symptoms, Evaluation, and Treatment Options. *Gastroenterol Hepatol.* 2020;16(2):9.
41. Wang WH, Huang JQ, Zheng GF, Xia HHX, Wong WM, Liu XG, et al. Effects of Proton-Pump Inhibitors on Functional Dyspepsia: A Meta-analysis of Randomized

- Placebo-Controlled Trials. *Clin Gastroenterol Hepatol.* 2007;5(2):178-85.
42. Mössner J. The Indications, Applications, and Risks of Proton Pump Inhibitors. *Dtsch Aerztebl Online.* 2016;113(27-28):477-83.
43. van Zanten SV, Armstrong D, Chiba N, Flook N, White RJ, Chakraborty B, et al. Esomeprazole 40 mg Once a Day in Patients with Functional Dyspepsia: The Randomized, Placebo-Controlled “ENTER” Trial. *Am J Gastroenterol.* 2006;101(9):2096-106.

Cite this article as: Mende J, Maturbongs GA, Mbulang YKA. Amiodarone causes QT prolongation in patients with atrial fibrillation complicating dyspepsia: a case report. *Int J Basic Clin Pharmacol* 2026;15:781-6.