

DOI: <https://dx.doi.org/10.18203/2319-2003.ijbcp20241001>

Case Report

## Drug induced bullous fixed drug eruption: a case report

Tamil Selvi Emperumal\*

Department of Pharmacology, All India Institute of Medical Sciences (AIIMS), Nagpur, Maharashtra, India

**Received:** 21 March 2024

**Revised:** 10 April 2024

**Accepted:** 11 April 2024

**\*Correspondence:**

Dr. Tamil Selvi Emperumal,

Email: [etamilselvi11@gmail.com](mailto:etamilselvi11@gmail.com)

**Copyright:** © the author(s), publisher and licensee Medip Academy. This is an open-access article distributed under the terms of the Creative Commons Attribution Non-Commercial License, which permits unrestricted non-commercial use, distribution, and reproduction in any medium, provided the original work is properly cited.

### ABSTRACT

Bullous fixed drug eruption, which is a cutaneous adverse drug reaction, is commonly seen with antimicrobials and analgesics. Bullous drug eruptions are infrequent, but because they pose a challenge both to affected patients and to treating physicians, they are considered to be the most severe cutaneous adverse reactions (SCAR). It is important to recognize these conditions and to differentiate them from other clinical entities involving blister formation. There may be early signs and symptoms that indicate a severe bullous drug eruption even before blisters and erosions of the skin and mucous membranes become obvious. Once the diagnosis is suspected, appropriate diagnostic procedures and adequate management must be initiated. The latter includes identification of the potentially inducing drug, although it should be taken into account that not all cases of bullous eruptions are drug-induced. In cases with drug causality the potentially culprit agent must be withdrawn, while in cases with other aetiology the underlying condition, e.g. an infection, must be treated appropriately. In addition to best supportive care, immunomodulating therapy may be considered. Here we report 64-year-old male with bullous fixed drug eruptions due to doxycycline administration

**Keywords:** Bullous fixed drug eruption, Doxycycline

### INTRODUCTION

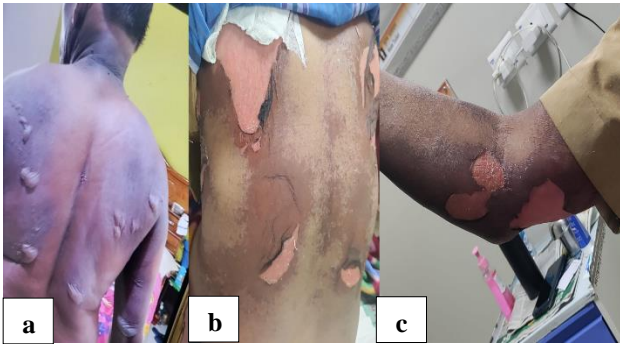
Doxycycline is a broad-spectrum antimicrobial drug and most commonly used to treat respiratory tract infections, intra-abdominal infections, rickettsial infections, skin and soft tissue infections, periodontal disease, sexually transmitted diseases and also used in prophylaxis of malaria.

Common adverse effects of doxycycline include gastrointestinal upset, hepatotoxicity, renal toxicity, teeth discoloration, hemolytic anemia, phototoxicity and skin rashes. Exacerbation of cutaneous lupus erythematosus had also been reported due to doxycycline therapy. However, fixed drug eruption due to doxycycline is a rare adverse event.<sup>1</sup>

### CASE REPORT

A 64-year-old elderly male took one dose of doxycycline 100 mg tab along with probiotic and pantoprazole and he noticed itching all over the body and reddish rash with development of small fluid filled lesions over trunk whereas palms, genital mucosa, oral cavity, nails and scalp were spared and this patient had a similar history in past and he has been allergic to sulpha, doxycycline drugs. Hence consulted the local hospital and found to have Pseudo Nikolsky sign and tidal test positive hence admitted and diagnosed as a case of fixed drug eruption and patient was treated with dexamethasone 8 mg intravenously once daily, azithromycin 1 gm once daily orally, tablet cefixime 400 mg BD, antihistamines, saline compresses and other supportive measures. The patient improved and recovered from skin lesions within ten days of admission. The steroid

was tapered and patient was discharged with the advice to avoid using doxycycline in future.



**Figure 1 (a-c): Bullous fixed drug eruption (FDE).**

**DISCUSSION**

Fixed drug eruption (FDE) is the most common cutaneous drug reaction seen in India. Predisposing genetic background probably reflects this adverse drug reaction. It is characterized by pruritic, well-circumscribed, erythematous patches at the same site with re-exposure to an offending drug.<sup>2</sup> Subsequent exposures may increase the number of sites.<sup>3</sup>

**Table 1: Naranjo’s algorithm for causality assessment.**

Naranjo’s algorithm for causality assessment	Yes	No	Unknown
The adverse event appeared after doxycycline was administered	+2	-1	0
Adverse event improved when doxycycline was discontinued	+1	0	0
Adverse event reappeared when doxycycline was re-administered	2	-1	0
Alternate causes that could solely have caused the reaction	-1	2	0
The patient had a similar reaction to the same or similar drugs in any previous exposure	1	0	0
The adverse event confirmed by objective evidence	1	0	0

The commonly used drugs causing FDE are antibiotics such as trimethoprim-sulfamethoxazole, penicillin, tetracycline and erythromycin followed by non-steroidal anti-inflammatory drugs (NSAIDs) and antiepileptics. In this case, patient developed adverse reaction within one day following administration of doxycycline.<sup>4</sup>

Naranjo’s algorithm was used to determine a plausible reaction due to doxycycline.

The following criteria were considered as described in Table 1.

Based on the total score of 7, this FDE was categorized as ‘probable’ reaction to doxycycline administration.

**CONCLUSION**

This case illustrates clinically important and rare cutaneous drug reaction of doxycycline, commonly prescribed antibiotic. Hence, it should be kept in mind that use of doxycycline can result in development of fixed drug eruption and should be prescribed cautious among the prescribing physician.

*Funding: No funding sources*

*Conflict of interest: None declared*

*Ethical approval: Not required*

**REFERENCES**

1. Miller KK, Chu J, Patel R, Kamino H. Drug-induced subacute cutaneous lupus erythematosus related to doxycycline. *Dermatol Online J.* 2011;17:3.
2. Pasricha JS. Drugs causing fixed eruptions. *Br J Dermatol.* 1979;100:183-5.
3. Naranjo CA, Busto U, Sellers EM. A method for estimating the probability of adverse drug reactions. *Clin Pharmacol Ther.* 1981;30:239-45.
4. Mockenhaupt M. Bullous Drug Reactions. *Acta Derm Venereol.* 2020;100(5):adv00057.

**Cite this article as:** Emperumal TS. Drug induced bullous fixed drug eruption: a case report. *Int J Basic Clin Pharmacol* 2024;13:398-9.