

Effect of tylophora asthmatica on hepatotoxicity induced by antitubercular drugs in albino rats

Ajay R. Chandrakapure^{1*}, Vijay M. Motghare², Sudhir L. Padwal³,
Avinash V. Turankar², Vinod S. Deshmukh⁴

¹Department of Pharmacology,
IIMSR, Warudi, Jalna,
Maharashtra, India

²Department of Pharmacology,
GMC, Nagpur, Maharashtra,
India

³Department of Pharmacology,
SRTRMCH, Ambajogai,
Maharashtra, India

⁴Department of Pharmacology,
GMC, Latur, Maharashtra, India

Received: 30 April 2016

Accepted: 03 June 2016

***Correspondence to:**

Dr. Ajay R. Chandrakapure,
Email: drajayrc3412@gmail.com

Copyright: © the author(s),
publisher and licensee Medip
Academy. This is an open-
access article distributed under
the terms of the Creative
Commons Attribution Non-
Commercial License, which
permits unrestricted non-
commercial use, distribution,
and reproduction in any
medium, provided the original
work is properly cited.

ABSTRACT

Background: The burden of metabolism and exposure to dangerous chemicals make liver vulnerable to variety of disorders like acute or chronic inflammation, toxin/ drug related hepatitis or cirrhosis. Tuberculosis is a common problem in India and worldwide. Drug induced liver injury (DILI) is a problem of increasing significance, but has been a long standing concern in treatment of tuberculous (TB) infection. Several studies have revealed that, tylophora asthmatica (Burnf.) Merrill. (Family: asclepidaceae) commonly known as anmul possess hepatoprotective property. There is less scientific work regarding the effect of Tylophora asthmatica on hepatotoxicity induced by antitubercular drugs, hence the present study was carried out with the aim of evaluating the effect of tylophora asthmatica on antitubercular drug induced hepatotoxicity in albino rats.

Methods: Total 24 Albino rats weighing about 150-200 grams were divided in four groups, 6 animals in each group. In the study, antitubercular drugs: INH (50 mg/kg) and rifampicin (50 mg/kg), test drug: aqueous extract of tylophora asthmatica doses (200 mg/kg and 300 mg/kg) were used. Drugs were given by oral route for 14 days. Biochemical tests for Sr. ALT, AST, bilirubin (total and direct) and histopathological examination of liver was done.

Results: Tylophora asthmatica treated group had no significant rise in values of Sr.ALT, AST, bilirubin (total and direct) and also there were no significant histopathological changes in this group, indicating hepatoprotective effect of tylophora asthmatica.

Conclusions: It was concluded that tylophora asthmatica has hepatoprotective activity in antitubercular drug induced hepatotoxicity.

Keywords: Tylophora asthmatica, Antitubercular drugs, Hepatotoxicity, ALT, AST, Bilirubin

INTRODUCTION

Liver is one of the most important organs in the biotransformation of food, drugs, endogenous and exogenous substances. Profuse supply of blood and presence of many redox systems (e.g. cytochromes and various enzymes) enable liver to convert these substances into different kinds of inactive, active or even toxic metabolites. Drugs can cause toxic effects, which can mimic almost every naturally occurring liver disease.¹

Drug induced liver injury (DILI) is a problem of increasing significance, but has been a long standing concern in treatment of tuberculous (TB) infection.² Unfortunately, INH is associated with significant hepatotoxicity in up to 2% of individuals exposed, and if this adverse event is not recognized early it can be fatal.³ Rifampicin a powerful inducer of mixed function oxidase, contributes to hepatotoxicity of INH by enhancing the production of toxic metabolites.⁴ Oxidative stress is one of the mechanisms with a central role involved in the pathogenesis of antitubercular

drugs (isoniazid and rifampicin)-induced hepatitis.⁵ Oxidative stress has been proposed as a likely process to explain progression to hepatocellular damage inflammation and fibrosis.⁶ Presently only few hepatoprotective drugs are available for treatment of liver disorders.⁷ *Tylophora indica* (Burnf.) Merrill. (Family: asclepidaceae) commonly known as antmul is a twining perennial plant distributed throughout southern and eastern part of India in plains, forests, and hilly places.⁸ In ayurveda, the plant has been used in treatment of asthma, dermatitis, and rheumatism. The other reported activities include immunomodulatory activity, anti-inflammatory activity, anticancer activity, and antiamebic activity.⁹ Although the leaf and root of this plant are widely used for treating jaundice in North-eastern Karnataka, there is a paucity of scientific evidence regarding its usage in liver disorders.⁷ Only few studies have been carried out on *tylophora asthmatica* for its hepatoprotective properties. However as per the available studies there is less scientific research work available to test the effect of *tylophora asthmatica* as an antitubercular drug induced hepatotoxicity in rats.^{1,7-9}

Hence the present study was carried out with aim of evaluating the Effect of *tylophora asthmatica* on hepatotoxicity induced by antitubercular drug.

METHODS

The study was approved by the institutional ethics committee and institutional animal ethical committee.

The animals used in the study were healthy adult albino rats of either sex and weighing about 150-200 grams each. The animals were kept on balanced diet and water ad libitum in well-ventilated animal unit.

Antitubercular drugs were used to induce hepatotoxicity

- INH Powder 50 mg/kg.
- Rifampicin Powder 50 mg/kg Sodhi et al.⁶

Both the drugs were obtained in pure powdered form from MACLEODS pharmaceuticals Pvt Ltd and THEMIS MEDICARE Ltd, Mumbai, India. Both the drugs were given by oral route in normal saline.

Test drug: Aqueous extract of tylophora asthmatica (AqETA)

Aqueous extract of *tylophora asthmatica* (manufactured by ANSAR INDUSTRIES, Ltd. Gujarat, and MFG. Date: February 2010) was received from the company for the study.

Dose-200 mg/kg/day P.O. and 300 mg/kg/day P.O. Mujeeb et al.⁹

Collection of blood and liver samples

Blood was collected directly from heart of rat anaesthetized with ether. Abdomen was opened by taking a midline incision. Diaphragm was cut with precaution and blood was collected slowly from ventricle by 24 gauge needle. Blood was sent to biochemistry department in plain bulb for biochemical analysis. Liver was dissected from rat and kept in 10% formalin and sent to pathology department for histopathological examination.

Study design

A total of 24 animals were included in the study. The concept of 3 Rs by Russel and Burch (1959) was followed so as to minimize the number of animals to be used in the study. The 3 Rs stand for refinement, reduction, and replacement.¹⁰

The animals were divided into four groups (6 animals in each group). 14 days treatment was given.

- Group-I - Vehicle control (normal saline 1ml)
- Group-II - (INH 50 mg/kg body weight+rifampicin 50 mg/kg body weight)
- Group-III - (INH 50 mg/kg body weight+rifampicin 50 mg/kg body weight)+aqueous extract of *tylophora asthmatica* 200 mg/kg body weight)
- Group-IV - (INH 50 mg/kg body weight+rifampicin 50 mg/kg body weight)+aqueous extract of *tylophora asthmatica* (300 mg/kg body weight).⁴

Doses of the antitubercular drugs were taken from antitubercular drug induced hepatotoxicity models. All drugs were given orally in normal saline for 14 days.⁶

On 14th day liver function tests (estimation of biochemical enzymes) was done by collecting blood samples from heart and also histopathological examination of liver was carried out.

The blood samples were investigated for (liver function tests) following parameters.

Biochemical investigations

The following biochemical parameters were used.

- Serum alanine aminotransferase (ALT). (Reitman and Frankel).¹¹
- Serum aspartate aminotransferase (AST). (Reitman and Frankel).¹¹
- Serum bilirubin (Total and Direct).

*(Bancroft's Histotechnique) for histopathological assesment of Liver specimen*¹²

Histopathological assessment of liver damage was done by using H and E staining, paraffin block method .The

liver specimens were sent in 10% formalin for histopathological examination.

Statistical analysis

The statistical analysis was carried out by using one-way analysis of variance (ANOVA). The values were represented as mean and comparison of mean values of different groups treated with normal saline (control), antitubercular drugs, and tylophora asthmatica was performed by Tukey's multiple comparison tests. Probability value i.e $p < 0.05$ was considered significant.^{13,14}

RESULTS

The statistical analysis for the biochemical parameters showed that

- Sr. ALT/SGPT - Gr1 versus Gr2- $p < 0.001$, Gr2 versus Gr3- $p < 0.001$, Gr2 versus Gr4- $p < 0.001$
- Sr. AST/SGOT - Gr1 versus Gr2- $p < 0.001$, Gr2 versus Gr3- $p < 0.001$, Gr2 versus Gr4- $p < 0.001$
- Sr. Bilirubin (Total) - Gr1 versus Gr2- $p < 0.01$, Gr2 versus Gr3- $p < 0.01$, Gr2 versus Gr4- $p < 0.01$
- Sr. Bilirubin (Direct) - Gr1 versus Gr2- $p < 0.001$, Gr2 versus Gr3- $p < 0.01$.

Results for the biochemical parameters Sr ALST, AST bilirubin (Total and Direct) showed that there was significant difference between group- 1 (vehicle control - normal saline) and group- 2 ATD treatment group (INH 50 mg/kg+rifampicin 50 mg/kg) indicating hepatotoxicity due to antitubercular drugs.

Table 1: Effect of simultaneous administration of antitubercular drugs and Tylophora asthmatica on Serum. ALT, AST, Bilirubin (Total and Direct).

Groups n=6	Treatment given	Sr. ALT/SGPT units/ml	Sr. AST/SGOT units/ml	Sr. bilirubin total (mg/dl)	Sr. bilirubin direct (mg/dl)
Gr-1	Vehicle control (normal saline)	20±1.78	30.67±2.73	1.75±0.13	0.79±0.17
Gr-2	ATD (INH 50 mg/kg+rifampicin 50 mg/kg)	118.7±5.46	109.3±10.78	2.36±0.40	1.12±0.11
Gr-3	ATD+AqETA 200 mg/kg	20.67±1.033	36.67±5.16	1.83±0.23	0.83±0.12
Gr-4	ATD+AqETA 300 mg/kg	20.6±1.03	20.67±1.033	1.75±0.13	0.95±0.06

(All values are Mean ±SD) **One - way ANOVA** .Post hoc-Tukey's Multiple comparison test. **P=Probability value** i.e p value < 0.05 was considered significant. **SD**=Standard Deviation; **ATD**=Antitubercular Drugs AqETA=Aqueous Extract of Tylophora asthmatica; **ALT**=Serum alanine aminotransferase; **SGPT**=Serum Glutamate Pyruvate Transaminase; **AST**=Serum aspartate aminotransferase; **SGOT**= Serum Glutamate Oxaloacetic Transaminase.

There was significant difference between group- 2 ATD treatment group (INH 50 mg/kg+rifampicin 50 mg/kg) and group-3 (ATD+AqETA 200 mg/ml treated group).

There was also significant difference between group- 2 i.e ATD treatment group (INH 50 mg/kg+rifampicin 50 mg/kg) and group 4 (ATD + AqETA 300 mg/kg) for the biochemical parameters Sr. ALT, AST, and Sr. bilirubin (Total) indicating hepatoprotective property of tylophora asthmatica.

Administration of antitubercular drugs significantly elevated the levels of serum alanine aminotransferase, serum aspartate aminotransferase, and Sr. bilirubin (Total and Direct). Co-administration of tylophora asthmatica along with antitubercular drugs significantly prevented this rise.

Also the histopathological changes like (portal inflammation, ballooning degeneration fatty change and necrosis degeneration which were seen due to administration of antitubercular drugs were not significant

with the concurrent use of tylophora asthmatica (Figures 1,2,3,4,5).

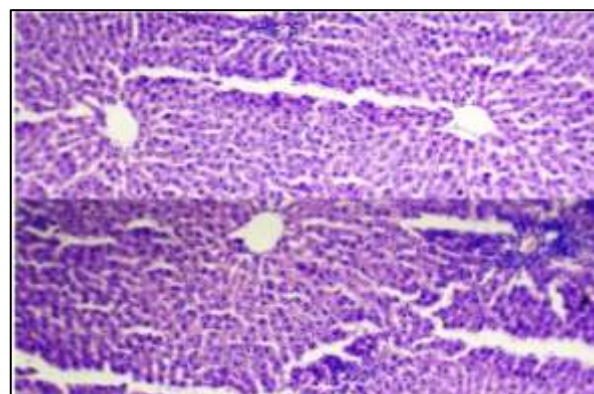


Figure 1: H and E stained section shows normal hepatic lobules and sinusoids (10 x) in rats fed with normal saline (control group).

The results can be described as follows.

Effect of antitubercular drugs in albino rats after 14 days

Antitubercular drugs Treatment for 14 days caused

- Rise in levels of Serum Alanine Aminotransferases (Sr.ALT)
- Rise in levels of Serum Aspartate Aminotransferases (Sr.AST)
- Increase in serum bilirubin (Total and Direct) level.

All these alteration in parameters were statistically significant as compared to vehicle control (normal saline) group.

- Histopathological changes like portal inflammation, ballooning, degeneration fatty change and necrosis were observed.

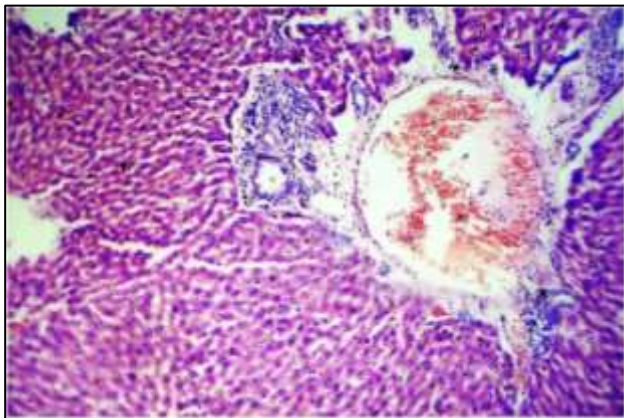


Figure 2: H and E stained of portal area of liver with inflammatory infiltrate like lymphocytes, macrophage and few polymorphs (10 x) in rats fed with antitubercular drugs INH+Rifampicine 50 mg/kg each.

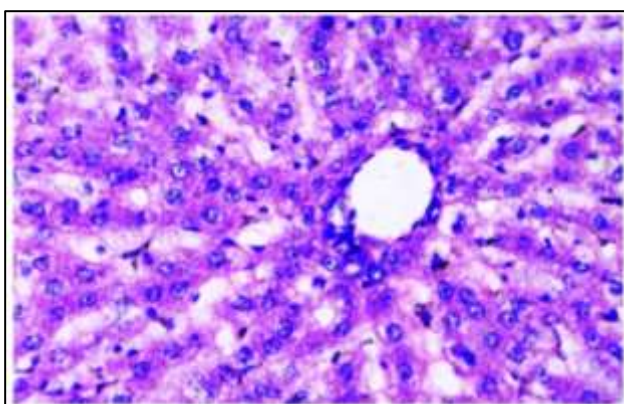


Figure 3: H and E stained section of ballooning degeneration in liver tissue (40 x) in rats fed with antitubercular drugs (INH 50 mg/kg+Rifampicin 50 mg/kg).

Effect of simultaneous administration of antitubercular drugs and tylophora asthmatica

Administration of antitubercular drugs significantly elevated the levels of serum alanine aminotransferase, serum aspartate aminotransferase, and Sr. bilirubin (Total and Direct). Co-administration of tylophora asthmatica along with Antitubercular drugs significantly prevented this rise.

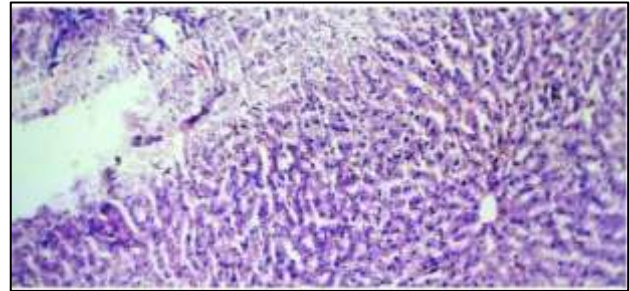


Figure 4: H and E stained of bridging necrosis in liver tissue (40 x) in rats fed with antitubercular drugs INH+Rifampicine 50 mg/kg each.

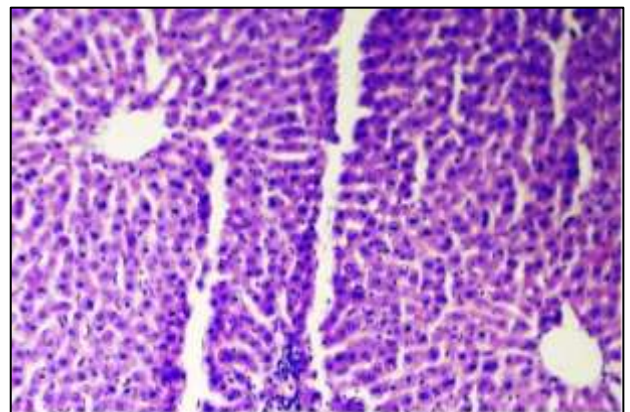


Figure 5: H and E stained section of apparently normal hepatocytes (10 x) in rats fed with antitubercular drugs INH+Rifampicine 50 mg/kg each+tylophora asthmatica 200 mg/kg.

Also the histopathological changes like (portal inflammation, ballooning degeneration fatty change and necrosis degeneration which were seen due to administration of antitubercular drugs were not significant with the concurrent use of tylophora asthmatica.

DISCUSSION

Drug-induced liver disease, a potential complication with some medications, is a common cause of hepatic injury. More than 1,000 drugs have been implicated in drug-induced liver injuries. Drugs mainly causing hepatotoxicity include antitubercular drugs, paracetamol, anticancer agents and anti HIV drugs etc.¹⁵

In the present study administration of antitubercular drug combination of isoniazid and rifampicin for 14 days significantly elevated the levels of serum alanine aminotransferase (ALT), serum aspartate aminotransferase (AST) and bilirubin (Total and Direct) indicating hepatotoxicity.

Some studies revealed that AST, ALT, ALP, LDH increases in hepatic serum due to leakage of enzymes from liver as a result of tissue damage. Administration of INH and Rifampicin combination showed a significant derangement of liver function as assessed by change in serum enzymes arginine succinic acid lyase (ASAL) and ALT.^{4,16} The findings of present study are similar to these studies.

Liver histopathology can serve as most important tool for identifying and characterizing liver injury whether or not clinical chemistry is identified.¹⁷ Kalra et al, found that histological changes in the liver were more common with isoniazid-rifampicin combination than with isoniazid only.¹⁸ In another study by Pal et al it was seen that the treatment with (INH 50 mg/kg+ RIF 50 mg/kg) caused portal triaditis and liver necrosis.¹⁹

In the present study administration of antitubercular drugs resulted in portal inflammation, ballooning degeneration, fatty change and necrosis in rat liver, which supports the findings of previous studies.^{18,19}

In the present study it was also found that there were no significant changes like portal inflammation, ballooning degeneration, fatty change and necrosis in groups treated with aqueous extract of tylophora asthmatica for 14 days. The results of hepatocellular damage caused by CC 14 and its recovery by methanolic extract of tylophora asthmatica suggested that the drug might be considered a potential source of natural hepatoprotective agents.⁹ Gujrati et al found that the histological changes such as steatosis (fatty changes in hepatocytes) and perivenular fibrosis observed in ethanol treated (toxic) group were prevented by the extracts of tylophora asthmatica indicating the hepatoprotective activity of tylophora asthmatica.⁷ The results of present study are in accordance with results of the above studies thus suggesting the hepatoprotective activity of tylophora asthmatica.^{7,9}

In the present study, the groups with concurrent treatment with tylophora asthmatica showed no significant rise in the levels of Serum ALT, AST, bilirubin (Total and Direct).

In another study the hepatic damage caused by CCl₄ was evidenced by an elevation in the serum marker enzymes (SGPT, SGOT, Bilirubin, and MDA). Methanolic extract of tylophora asthmatica significantly reduced these liver enzyme levels in the serum in a dose dependant manner, which indicates hepatoprotection.⁹

Gomez et al, observed that methanolic extract of tylophora asthmatica significantly decreased the liver enzymes Sr. ALT, Sr. AST and increased antioxidant defence system in paracetamol treated rats.¹ In another study by Gujrati et al tylophora asthmatica showed hepatoprotective effect as it significantly lowered the values of serum AST and ALT and serum bilirubin, which were increased following ethanol administration.⁷ The results of present study are similar to the above studies and reveals that tylophora asthmatica significantly prevents hepatotoxicity induced by antitubercular drugs in rats.^{1,7,9}

Since most of the drugs used in the treatment of tuberculosis are shown to have hepatotoxic effects, studies have been performed to prevent or reduce the toxicity by the use of natural herbal drugs and/or synthetic compounds like Picrorhiza kurroa, Garlic, Silymarin, and several other herbal drugs are proved to have such effects, according to Jeyakumar et al, Pal et al, Kothekar et al.^{5,19,20}

The observed hepatoprotective/antioxidant activity of META against paracetamol-induced hepatotoxicity might be due to synergistic action of various components in the META and mainly of the phenanthroindolizidine (tylophorine and tylophorinidine) alkaloids.¹ The presence of secondary metabolites like alkaloids, steroids, saponins, and triterpenes in these extracts may be responsible for the hepatoprotective activity probably due to antioxidant defence property Gujrati et al.⁷

In the present study, it was found that concurrent tylophora asthmatica significantly prevented rise liver enzyme Sr. ALT, Sr. AST and Sr. bilirubin in Antitubercular drugs treated rats. There were no significant changes like portal inflammation, ballooning degeneration, fatty change and necrosis in groups concurrently treated with aqueous extract of tylophora asthmatica and antitubercular drugs.

CONCLUSION

With the study, knowledge and results of above references and observations made and results obtained in the present study, it was concluded that tylophora asthmatica has a significant hepatoprotective effect on antitubercular drug induced hepatotoxicity.

ACKNOWLEDGEMENTS

Dean S. R. T. R. Medical College Ambajogai, Dr. V. V. Wase, who permitted us to carry out the study in institute. Dr. J.B. Jaju. Dr. Mogarekar, Dr. Shyam Kulkarni and Dr. Mahesh Hampe, Dr. Rasika. U. Gadkari, Dr. Zadke, Dr. Anup Kediya, Dr. Shankar Gaikwad, Dr. Nadeem Khan, Dr. Rakesh Jadhav, Mr R.K. Gade, M.S. Shinde, Dr. R.R. Bhosale, Dr. Rakesh R Pore, Dr. Rushikesh Deshpande, Dr. Chetan Bhamare, Dr.Suvarna Rathod, Dr D.B. Jadhav, Mr. Deshpande, Mr. S. D.

Shrotre, Mr. Laddha, Mr. H.M. Pandit, Macleods Pharmaceuticals and Themis Medicare Pvt Ltd Mumbai for supplying drugs.

Funding: No funding sources

Conflict of interest: None declared

Ethical approval: The study was approved by the Institutional Ethics Committee

REFERENCES

1. Malathi R, Gomez MP. Hepatoprotective effect of methanolic leaves extracts of tylophora asthmatica against paracetamol-induced liver damage in rats. *J Pharmacol Toxicol.* 2007;2(8):737-42.
2. Jussi J, Saukkonen, Cohn DL, Jasmer RM, Schenker S, Jereb JA, et al. An official ATS statement: hepatotoxicity of antituberculosis therapy. *Am J Respir Crit Care Med.* 2006;174:935-52.
3. Sarich TC, Zhou T, Adams SP, Bain AL, Wall RA, Wright JM. A model of isoniazid-induced hepatotoxicity in rabbits. *J Pharmacol Toxicol Methods.* 1995;34(2):109-16.
4. Tayal V, Kalra BS, Agarwal S, Khurana N, Gupta U. Hepatoprotective effect of tocopherol against isoniazid and rifampicin induced hepatotoxicity in albino rabbits. *Indian J Exp Biol.* 2007;45(12):1031-6.
5. Jeyakumar R, Rajesh R, Meena B, Rajaprabhu D, Ganesan B, Buddhan S, et al. Antihepatotoxic effect of picrorrhiza kurroa on mitochondrial defense system in antitubercular drugs (isoniazid and rifampicin)-induced hepatitis in rats. *J Med Plants Res.* 2008;2(1):17-19.
6. Sodhi CP, Rana SV, Mehta SK, Vaiphei K, Attari S, Mehta S. Study of oxidative-stress in isoniazid-rifampicin induced hepatic injury in young rats. *Drug and chemical toxicology.* 1997;20(3):255-69.
7. Vipul G, Patel N. Hepatoprotective activity of alcoholic and aqueous extracts of leaves of tylophora indica in rats. *Indian J Pharmacol.* 2007;39(1):43-7.
8. Gupta M, Mukhtar HM, Sayeed A. Phytopharmacological and plant tissue culture overview of Tylophora indica (burn f.) Merrill. *J Pharm Sci and Res.* 2010;2(7):401-11.
9. Mujeeb M, Aeri V, Bagri P, Khan SA. Hepatoprotective activity of the methanolic extract of Tylophora indica (Burm. f.) Merrill. leaves. *Int J Green Pharm.* 2009;3:125-7.
10. Ghosh MN. *Fundamentals of experimental pharmacology* 4th ed. Hilton and company Kolkota. 2008;25:184.
11. Reitman S, Frankel S. In vitro determination of transaminase activity in serum. *Am J Clin Pathol.* 1957;28:56-60.
12. Marilyn G. The hematoxylin and eosin. In: John D Bancroft, Marilyn Gamble editors. *Theory and practice of Histological Techniques.* 6th ed. Churchill Livingstone Elsevier; 2008:121-134.
13. Raju VP, Raghu H, Chandrashekar, Vijayan P, Dhanraj SA, Rao MC, et al. In vitro and vivo. Hepatoprotective effects of the total alkaloid fraction of Hygrophila auriculata leaves. *Indian J Pharmacol.* 2010;42(2):99-104.
14. Mahajan BK. *Methods in Biostatistics.* 6th ed. Jaypee Brothers Significance of difference in mean. 2006;9:130-55.
15. Jiwon K. An overview of drug-induced liver disease; *US Pharm.* 2005;30:11.
16. Saraswathy SD, Suja V, Gurumurthy P, Shyamala Devi CS. Effect of liv.100 against antitubercular drugs (isoniazid, rifampicin and pyrazinamide) induced hepatotoxicity in rats. *Research paper Indian J Pharmacol.* 1998;30:233-8.
17. Simon JB. Drug-induced liver disease. In: *First Principles of Gastroenterology* 4th ed. 2000;507-11.
18. Kalra BS, Aggarwal S, Khurana N, Gupta U. Effect of cimetidine on hepatotoxicity induced by isoniazid-rifampicin combination in rabbits. *Indian J Gastroenterol.* 2007;26(1):18-21.
19. Pal R, Vaiphei K, Sikander A, Singh K, Rana SV. Effect of garlic on isoniazid and rifampicin-induced hepatic injury in rats. *World J Gastroenterol.* 2006;12(4):636-9.
20. Kothekar MA, Syed RU, Jaju JB, Mateenuddin MD. Effect of the antioxidants alpha-tocopherol acetate and sodium selenite on hepatotoxicity induced by antitubercular drugs in rat. *Indian J Physiol Pharmacol.* 2004;48(1):119-22.

Cite this article as: Chandrakapure AR, Motghare VM, Padwal SL, Turankar AV, Deshmukh VS. Effect of tylophora asthmatica on hepatotoxicity induced by antitubercular drugs in albino rats. *Int J Basic Clin Pharmacol* 2016;5:1402-7.